

*Full Paper*

## **Preliminary biochemical and histological effects of consumption of *Talinum triangulare* (L.) Juss – supplemented diet on paracetamol-induced hepatotoxicity in rats.**

Emeka E.J. Iweala and Oluwademilade.Y. Lawal

Department of Biological Sciences, Biochemistry and Molecular Biology Unit,  
Covenant University, P.M.B 1023, Ota, Ogun State, Nigeria.

*Accepted March 2011*

This preliminary study was undertaken to investigate some biochemical and histological effects of consumption of *Talinum triangulare* (L.) Juss – supplemented diet in hepatotoxic rats in which liver damage was induced with paracetamol. Thirty female rats were divided into six groups of five rats per group for control, hepatotoxic and non-hepatotoxic groups and were fed 5% or 10% *T. triangulare*-supplemented diet. Biochemical and hematological indices measured included alanine transaminase, aspartate transaminase, total protein, glucose, total triglycerides, total cholesterol, reduced glutathione, lipid peroxidation, packed cell volume, white blood cell and differentials count. Weight changes were also measured. Alanine transaminase and aspartate transaminase did not significantly change except for the hepatotoxic group fed 5% *T. triangulare*-supplemented diet. Cholesterol and triglycerides were significantly increased in non-hepatotoxic group fed 5% *T. triangulare*-supplemented diet. Glucose was significantly reduced in non-hepatotoxic groups fed *T. triangulare*-supplemented diet and hepatotoxic group fed 10% *T. triangulare*-supplemented diet. Protein level was also reduced in group fed 10% *T. triangulare*-supplemented diet. Lipid peroxidation and reduced glutathione were not significantly altered in all the groups. PCV and white blood cell counts were reduced in hepatotoxic group fed *T. triangulare*-supplemented diet. The consumption of *T. triangulare*-supplemented diet did not significantly change the weight of the animals. These findings were supplemented by histological observations of liver tissues which showed necrosis in the liver of hepatotoxic rats but with varying regeneration in the rat group fed with *T. triangulare*-supplemented diet.

**Keywords:** *Talinum triangulare*, alanine transaminase, triglycerides, packed cell volume, cholesterol, lipid peroxidation.

### **Introduction**

Plant foods especially tropical vegetables contain a large array of chemically diverse bioactive compounds with potential health promoting properties [1, 2]. Leafy vegetables contribute to meeting the nutritional and medicinal needs of sub-tropical local populations especially in Nigeria as staples, flavours, condiments, spices, drinks and beverages in most de-

veloping countries [3]. *Talinum triangulare* (L.) Juss is one of vegetables widely cultivated and consumed in Africa especially Southern Nigeria [4]. *T. triangulare* is a cosmopolitan weed belonging to the *Talinum* genus, family Portulacaceae that grows best under humid conditions [5]. The leaves of *T. triangulare* is eaten as a vegetable and employed in the treatment of several disease conditions such as measles, sexually transmitted diseases

and internal heat and is associated with varying biochemical and physiological effects [6,7]. The varying uses of the leaves of *T. triangulare* underscore its importance as major dietary supplement as a result of its nutritional and phytochemical composition [8].

Paracetamol (Acetaminophen) is a drug that is widely employed in relief of pain and feverish conditions. The over-the-counter widespread procurement of paracetamol predisposes to excessive use and overdose which can cause liver toxicity and damage [9]. In Nigeria, hepatic toxicity and other biochemical effects resulting from the abuse of paracetamol may be masked due to its high tolerance and widespread consumption of plant based diets such as leaves of *T. triangulare*. This is the basis of this preliminary study aimed at investigating the preventive potentials and other associated effects of consumption of leaves of *T. triangulare* against paracetamol-induced hepatotoxicity in rats.

## MATERIALS AND METHODS

This study was carried out between 7<sup>th</sup> December, 2009 and 7<sup>th</sup> March, 2010 at the department of Biological Sciences, Covenant University, Ota, Ogun State, Nigeria.

### Processing of *T. triangulare* leaves.

Fresh leaves of *T. triangulare* obtained from a market in Ota, Ogun state, South-Western Nigeria were picked, air-dried and ground to a coarse powdered form with an Achtung hammermill. The proximate composition of the *T. triangulare* leaf powder was determined according to the procedure outlined in AOAC [10] and applied in the formulation of experimental diets.

### Formulation of Experimental diets

Three experimental diets namely control diet, 5% and 10% *T. triangulare*-supplemented diets were formulated with commercially available feedstuffs which include maize, corn flour, fish meal, groundnut meal, bone meal and vitamin premix. The control diet was formulated without incorporation of *T. triangulare* leaf powder while the *T. triangulare*-supplemented diets were formulated with either 5% and 10% of *T. triangulare* leaf powder.

### Study design

Thirty female albino rats aged four to six weeks old and with an average weight of 40-80g were selected for the study. The animals were housed in well ventilated stainless steel cages and exposed to twelve hours light and dark cycles under tropical weather conditions. A set of five rats per group were each randomly distributed into six experimental groups including non-hepatotoxic control, hepatotoxic control, non-hepatotoxic I, non-hepatotoxic II, hepatotoxic A and hepatotoxic B. The animals in non-hepatotoxic control and hepatotoxic control groups were fed control diet while those in non-hepatotoxic I and hepatotoxic A groups were fed 5% *T. triangulare* - supplemented diet. The animals in non-hepatotoxic II and hepatotoxic B groups were fed 10% *T. triangulare* - supplemented diet. The groups and their diets are shown in table 1. All the animals were given their various feed and water *ad libitum* for fifty-six (56) days. Seven days prior to the end of feeding, liver damage was induced in animals in the hepatotoxic experimental groups by daily oral administration with 3g/kg body weight of paracetamol while those in non-hepatotoxic groups were administered with the vehicle (distilled water) only. The weight of animals in all the groups were measured weekly throughout the study period. The animal experiments were approved by the institutional animal ethics committee in accordance with the guide-

lines of Committee for the Purpose of Supervision and Control of Experiments on Animals (CPCSEA) [11].

**Table 1.** Experimental groups and diets.

Group	Diet
Non-hepatotoxic Control	Control diet
Hepatotoxic Control	Control diet
Non-hepatotoxic II	5% <i>T. triangulare</i> - supplemented diet
Non-hepatotoxic II	10% <i>T. triangulare</i> - supplemented diet
Hepatotoxic A	5% <i>T. triangulare</i> - supplemented diet
Hepatotoxic B	10% <i>T. triangulare</i> - supplemented diet

### Collection of blood and tissue samples

At the end of the study, the animals were anesthetized and blood samples collected in heparinised bottles. Serum samples were collected in non-heparinised bottles and allowed to clot before being centrifuged at 5000 rpm for 10 minutes. The livers were quickly excised, washed and preserved in 10% formyl saline for histological studies.

### Determination of enzymes and biomolecules

Serum levels of aspartate aminotransferase (AST) and alanine aminotransferase (ALT) and blood glucose levels were determined using GOT (HBE06) and GPT (HBE07) test kits supplied by Cypress diagnostics, Belgium. Triglycerides and cholesterol were determined using Cromatest test kits produced by Linear chemicals SL, Spain. Total protein was determined by the Lowry method without modification [12]. Reduced glutathione was determined using the method described by Ellman with modification [13]. Lipid peroxidation was determined by the method of Buege and Aust without modification [14].

### Determination of haematological parameters

Full blood and white blood cells (WBC) counts were done according to methods described by Dacie and Lewis without modifications [15].

### Histological studies

Thin sections (5-10  $\mu$ ) of liver tissues were prepared by first dehydrating with different increasing concentrations of ethanol, staining with haematoxylin-eosin and finally mounted with molten paraffin wax in neutral medium (10% buffered formalin). Histological examinations were done on according to procedures described by Disbery and Rack without modification [16].

### Statistical analysis

Data obtained are expressed as Mean  $\pm$  standard error of mean (SEM) for triplicate determinations. One-way analysis of variance (ANOVA) for a completely randomized design was used to analyse data. Values were considered significant at  $P < 0.05$ . All the statistics were estimates using SPSS software (15.0, November, 2006).

## RESULTS

The effect of the various diets on weight before and after induction of hepatic damage is shown in table 2. The effect of the various diets on biochemical parameters in the non-hepatotoxic and hepatotoxic groups are presented in table 3. The result of the various feeds on haematological parameters in hepatotoxic and non-hepatotoxic groups are presented in table 4. The histological features of the liver of the animals in all the groups are shown in Figures 1-6.

**Table 2.** Effect of *Talinum triangulare* - supplemented diet on weight changes in the animals.

Group	Weight change before induction of hepatotoxicity (%)	Weight change after induction of hepatotoxicity (%)
Non-hepatotoxic Control	30.6	7
Hepatotoxic Control	28.6	12.7
Non-hepatotoxic I	5.9	4.2
Non-hepatotoxic II	15.5	5.4
Hepatotoxic A	11.3	-0.64 <sup>b</sup>
Hepatotoxic B	22.6	3.6 <sup>b</sup>

<sup>a</sup> Represents values that are significant ( $p < 0.05$ ) with respect to non-hepatotoxic control

<sup>b</sup> Represents values that are significant ( $p < 0.05$ ) with respect to hepatotoxic control

**Table 3.** Effect of *Talinum triangulare* - supplemented diet on biochemical parameters in the animals

Measurement	Non-hepatotoxic Control	Hepatotoxic Control	Non-hepatotoxic I	Non-hepatotoxic II	Hepatotoxic A	Hepatotoxic B
Glucose (mg/dl)	166.99±15.35	197.19±5.02	89.65±7.51 <sup>a, b</sup>	93.63±7.59 <sup>a, b</sup>	181.38±31.11	101.41±24.26 <sup>a, b</sup>
Protein (mg/ml)	5.53±0.09	5.40±0.42	5.30±0.58	4.20±0.30 <sup>a, b</sup>	5.53±0.44	5.32±0.14
Reduced glutathione (mM/ml)	0.01±0.001	0.01±0.001	0.01±0.001	0.01±0.001	0.01±0.001	0.01±0.003
Cholesterol (mg/dl)	264.95±6.43	274.23±30.93	322.37±22.08 <sup>a</sup>	259.99±13.08	293.75±12.95	287.11±6.98
Triglyceride (mg/dl)	258.48±20.54 <sup>b</sup>	575.70±162.53 <sup>a</sup>	268.37±13.43 <sup>b</sup>	286.41±10.68 <sup>b</sup>	285.47±27.86 <sup>b</sup>	349.31±62.78 <sup>b</sup>
Lipid peroxidation (mol/mL)	13.92±1.73	19.47±2.97	15.21±1.48	17.70±1.82	13.19±0.27	17.10±2.50
Aspartate transaminase (IU/L)	27.85±9.01	12.54±3.21	12.95±4.87	27.18±11.23	12.40±2.99	30.33±17.44
Alanine transaminase (IU/L)	7.20±0.74	16.33±4.75	9.80±1.96	14.70±1.61	25.08±7.91 <sup>a</sup>	15.16±8.03

<sup>a</sup> Represents values that are significant ( $p < 0.05$ ) with respect to non-hepatotoxic control.

<sup>b</sup> Represents values that are significant ( $p < 0.05$ ) with respect to hepatotoxic control.

<sup>ab</sup> Represents values that are significant ( $p < 0.05$ ) with respect to hepatotoxic and non-hepatotoxic control.

**Table 4.** Effect of *Talinum triangulare* - supplemented diet on haematological parameters in the animals.

Measurement	Non-hepatotoxic Control	Hepatotoxic Control	Non-hepatotoxic I	Non-hepatotoxic II	Hepatotoxic A	Hepatotoxic B
Packed cell volume (%)	42.50±2.84	39.00±2.08	38.40±2.36	37.40±2.79	34.75±0.85 <sup>a</sup>	35.40±1.12 <sup>a</sup>
White blood cells (10 <sup>3</sup> mm <sup>-3</sup> )	7500±204.1 <sup>b</sup>	6625±239.36 <sup>a</sup>	6900±291.55	6800±200.00 <sup>a</sup>	7375±239.36 <sup>b</sup>	6600±187.08 <sup>a</sup>
Lymphocytes (%)	80.00±0.71	78.75±0.85	78.00±1.00	80.40±0.68	78.25±0.25	79.60±1.17
Neutrophils (%)	20.00±0.71	21.25±0.85	21.40±0.81	19.20±0.20 <sup>b</sup>	21.25±0.25	21.00±0.63

<sup>a</sup> Represents values that are significant ( $p < 0.05$ ) with respect to non-hepatotoxic control

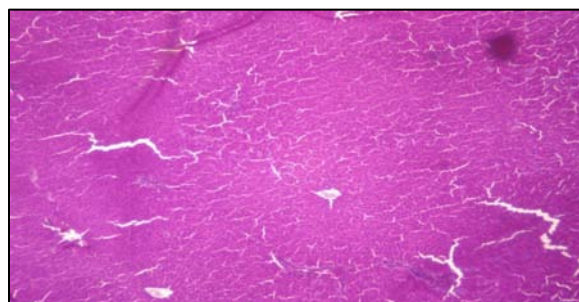
<sup>b</sup> Represents values that are significant ( $p < 0.05$ ) with respect to hepatotoxic control

## DISCUSSION

High doses of paracetamol is associated with hepatic damage in both animals and in humans [17]. The high dose of paracetamol generates a metabolite, *N*-acetyl-*p*-benzoquinoneimine (NAPQI), which is highly reactive and causes hepatotoxicity [18]. NAPQI can rapidly react with reduced glutathione (GSH) and lead to its depletion resulting in hepatocellular death and mitochondrial dysfunction [19]. Several plant products including vegetables have been investigated for their hepatoprotective properties using Paracetamol as a control [20]. *T. triangulare* is highly valued as a nutritious, medicinal and therapeutic vegetable across Central Africa [21]. The purpose of this investigation was to study the effect of *T. triangulare* on paracetamol-induced hepatotoxicity and other associated parameters in rats. Liver toxicity is assessed by measuring the serum levels of aspartate transaminase (AST) and alanine transaminase (ALT) [22]. Total proteins, triglycerides, cholesterol and glucose were used as supplementary tests for hepatic synthetic and other allied functions. Histological changes in the hepatocytes' morphology are the hallmarks of liver injury.

The feeding of *T. triangulare*-supplemented diet did not result in any significant ( $P < 0.05$ ) increases in weight of animals. This is due to the low content of nutrients in the leaves of *T. triangulare* when compared with other tropical vegetables [23]. Thus, this vegetable cannot

serve as a valuable source of nutrients for growth in animals.

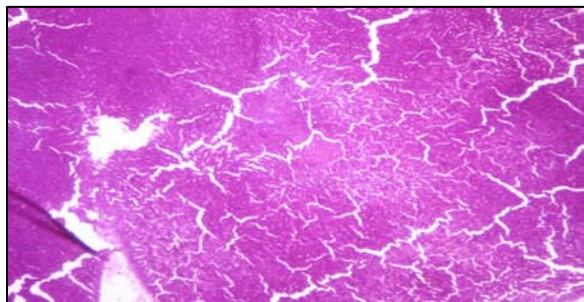


**Figure 1.** Photo micrograph of a cross section of liver of non-hepatotoxic rat fed with control diet. MAG. X40.

Generally the consumption of *T. triangulare*-supplemented diet did not significantly ( $p < 0.05$ ) change any of the liver enzymes in the animals indicating that it does not have any toxic effect on the liver. This study revealed a significant change ( $p < 0.05$ ) in the protein levels of non-hepatotoxic animals fed 10% *T. triangulare*-supplemented diet which is also related to the low nutrient content of the vegetable [23]. This finding agrees with the findings by Iweala *et al.* [24] showing reduction in the total protein levels of rats fed with leaves of *G. Africanum*, another commonly consumed tropical vegetable. Reduction in total protein could have consequences on the overall physiological function of the animals [25].

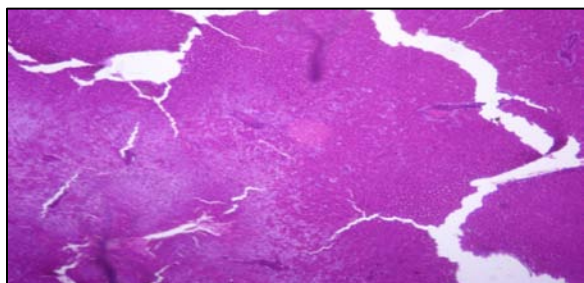
Depletion of reduced glutathione, an important antioxidant enzyme is associated with increased lipid peroxidation during paracetamol overdose and plays a role

in hepatotoxicity [26]. This study showed that there was stabilization in the level of lipid peroxidation and reduced glutathione in the animals. This could be attributed to the presence of antioxidant phytochemicals including phenolic substances, flavonoids and anthocyanidins in the *T. triangulare* [27].



**Figure 2.** Photo micrograph of a cross section of liver of non-hepatotoxic rat fed with 5% *T. triangulare* - supplemented diet. MAG. X40.

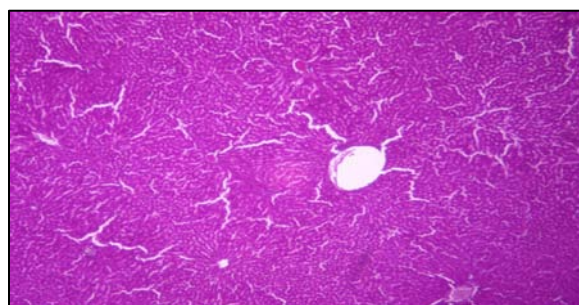
The reduction ( $p < 0.05$ ) in the levels of glucose in rats fed *T. triangulare*-supplemented diet suggests that its consumption could reduce the high glucose levels in diabetic conditions with associated liver damage. However this observation does not agree with the hyperglycaemic properties of *T. triangulare* reported by Ekpo *et al* [28].



**Figure 3.** Photo micrograph of a cross section of liver of non-hepatotoxic rat fed with 10% *T. triangulare* - supplemented diet. MAG. X40.

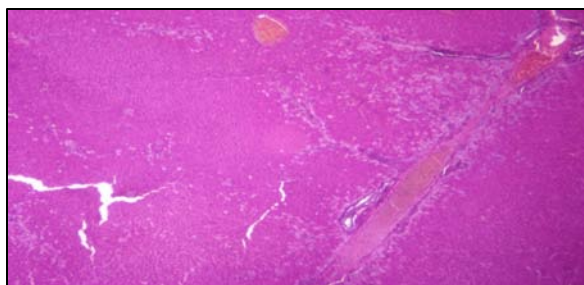
Generally, there were non-significant changes ( $p < 0.05$ ) in the levels of cholesterol in all of the groups and an increase in triglycerides of hepatotoxic control. *T. triangulare* generally have cholesterol stabilizing properties [28] while the increase in triglycerides is due to liver dysfunction.

PCV and WBC count are of diagnostic importance in paracetamol-induced toxicity and are affected by most bioactive phytochemicals [29, 30]. The reduced PCV ( $p < 0.05$ ) in animals fed *T. triangulare*-supplemented diet supports the haemolytic properties of the plant [28]. The non-significant change in the level of white blood cells of the animals infers that *T. triangulare* did not elicit any adverse reaction by the immune system of the animals [31]. An increase in the number of WBC is a normal reaction of rats to foreign substances, which alter their physiological processes [32].

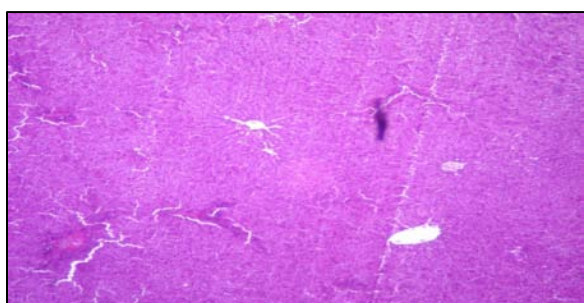


**Figure 4.** Photo micrograph of a cross section of liver of hepatotoxic rat fed with control diet. MAG. X40.

The liver of non-hepatotoxic animals fed with *T. triangulare*-supplemented diet showed normal histological features which corroborates that it does not have any apparent toxicity on the liver. In contrast, the hepatotoxic animals showed various levels of abnormal histological changes such as degeneration with some centrilobular necrosis and haemorrhages in the liver usually associated with the paracetamol challenge [33]. However, Figures 5 and 6 showed that the intensity of centrilobular necrosis was less in the liver sections of the hepatotoxic groups fed *T. triangulare*-supplemented diet. It is presumed that the consumption of *T. triangulare*-supplemented diet ameliorated the histological distortions caused by paracetamol because tropical green leafy vegetables are usually associated with hepatoprotective properties [34].



**Figure 5.** Photo micrograph of a cross section of liver of hepatotoxic rat fed with 5% *T. triangulare* - supplemented diet. MAG. X40.



**Figure 6.** Photo micrograph of a cross section of liver of hepatotoxic rat fed with 10% *T. triangulare* - supplemented diet. MAG. X40.

The results of this study suggest that *T. triangulare* may be used in the treatment or prevention of paracetamol-induced hepatotoxicity probably due to its ability to preserve the structural integrity of hepatocytes when challenged with hepatotoxicants. Further study is warranted to unravel the precise mechanism(s) for *T. triangulare* hepatoprotective effects in paracetamol-induced toxicity in rats. Furthermore, a bioassay guided fractionation is needed to identify the specific constituents of *T. triangulare* involved in this hepatoprotection against hepatic-induced toxicity.

## REFERENCES

1. Iweala EEJ. Preliminary qualitative screening for cancer chemopreventive agents in *Telfairia Occidentalis* Hook.f, *Gnetum africanum* Welw., *Gonronema latifolium* Benth. and *Ocimum gratissimum* L. from Nigeria. *J. Med. Food Plants.* 1 (2):58-63.2009.
2. Gupta S, Prakash JH. Studies on Indian green leafy vegetables for their antioxidant activity. *Plant Foods Hum Nutr* 64:39-45.2009
3. Mbang A, Owolabi S, Jaja O, Opeyemi JO. Evaluation of the antioxidant activity and lipid peroxidation of the leaves of *Vernonia amygdalina*. *J. Complem. Integ. Med,* 5. 2008.
4. Imoh EU, Julia OM. Nutrient requirement for the growth of water leaf (*Talinum triangulare*) in Uyo Metropolis, Nigeria. *The Environ.,* 21; 153-159. 2000.
5. Burkill HM. The Useful Plants of West Tropical Africa. Volume 2: Families E-I. Kew. Royal Botanic Gardens, Kew. ISBN: 0947643567.1994.
6. Mensah JK, Okoli RI, Ohaju-Obodo JO, Eifediyi K. Phytochemical, nutritional and medical properties of some leafy vegetables consumed by Edo people of Nigeria. *Afr. J. Biotechnol.* 7: 2304-2309.2008.
7. Oluwole FS, Falade AO, Ogundipe OO. Anti-inflammatory effect of some common Nigerian vegetables. *Nig. J. Physiol. Sci.,* 18: 35-38. 2003.
8. Folarin OM, Bamiro FO, Esuoso KO. Distribution of nutritive elements in water leaf. *Global J. Pure and Applied Sci.,* 7: 285-290. 2001.
9. Ryder S, Beckingham I. ABC of diseases of liver, pancreas, and biliary system. Other causes of parenchymal liver disease. *BMJ Clin. Res. Ed.* 322 (7281): 290-292. 2001.
10. AOAC. Official methods of analysis. 12<sup>th</sup> ed. Association of official agricultural chemists International, Washington D.C. 811-817. ISBN: 0935584242.1975.
11. CPCSEA. CPCSEA guidelines for laboratory animal facility. *Indian J. Pharmacol.,* 35: 257-274. 2003.
12. Lowry OH, Rosebrough NJ, Farr AL, Randall RJ. Protein measurement with the folin phenol reagent. *J Biol. Chem.,* 193: 265-275. 1951.
13. Ellman GL. Tissue sulfhydryl groups. *Arch. Biochem. Biophys.,* 82 (1):70-77. 1959.
14. Buege JA, Aust SD. Microsomal Lipid Peroxidation In: Fleischer P; Packer, L. (eds) *Methods in Enzymology* vol. 52 Academic press, New York, pp. 302 – 310. 1978.
15. Dacie JV, Lewis SM. *Practical Haematology.*7th Edn. Churchill Livingstone, London. ISBN: 0443039526. 1990.
16. Disbrey BD, Rack J.H. *Histological Laboratory Methods.* Livingstone , Edinburgh.pp 56-128. ISBN: 0443006946. 1970.

17. Ray SD, Mumaw VR, Raje RR, Fariss MW. Protection of acetaminophen-induced hepatic apoptosis and necrosis by cholesteryl hemisuccinate pretreatment. *J. Pharmacol. Exp. Ther.* 279:1470-1483. 1996.
18. Gupta AK, Misra N. Hepatoprotective activity of aqueous ethanolic extract of Chamomile capitula in paracetamol intoxicated albino rats. *Am. J. Pharmacol. Physiol.*, 1: 17-20. 2006.
19. Mitchell JR, Jollow DJ, Potter WZ, Gillette JR, Brodie BB. Acetaminophen-induced hepatic necrosis. IV. Protective role of glutathione. *J. Pharmacol. Exp. Ther.* 187 (1): 211- 217. 1973.
20. Suresh KSV, Sujatha C, Syamala J, Nagasudha B, Mishra SH. Protective effect of root extract of *Operculina turpethum* linn. against paracetamol-induced hepatotoxicity in rats. *Indian J Pharm. Sci*; 68:32-5. 2006.
21. Fasuyi A. Nutritional potential of some tropical vegetable meals. Chemical characterization and functional properties. *Afr. J. Biotechnol.* 5 (1): 49-53. 2006.
22. Agarwal M, Srivastava VK, Saxena KK, Kumar A. Hepatoprotective activity of *Beta vulgaris* against CCl<sub>4</sub>-induced hepatic injury in rats. *Fittoterapia* 77: 91-93. 2006.
23. Anyansor GN, Ogunwenmo KO. Comparative antioxidant, phytochemical and proximate analysis of aqueous and methanolic extracts of *Vernonia amygdalina* and *Talinum triangulare*. *Pak. J Nutr.* 9 (3):259-264. 2010.
24. Iweala EEJ, Uhegbu FO, Obidoa O. Biochemical and histological changes associated with long term consumption of *Gnetum africanum* Welw. leaves in rats. *Asian J. Biochem.* 4 (4):125-132. 2009.
25. Pachathundikandi SK, Varghese ET. Blood Zinc Protoporphyrin, Serum Total Protein, And Total Cholesterol Levels In Automobile Workshop Workers In Relation To Lead Toxicity: Our Experience. *Indian J. Clin. Biochem.* 21 (2):114-117. 2006.
26. Crocenz FA, Pellegrino JM, Sanchez Pozzi EJ, Mottino AD, Garay EA, Roma MG. Effect of silymarin on biliary salt secretion in the rat. *Biochem. Pharmacol.* 59(8):1015-1022. 2000.
27. Ayoola GA, Folawewo AD, Adesegun SA, Abioro OO, Adepoju-Bello AA, Coker HAB. Phytochemical and antioxidant screening of some plants of Apocynaceae from South West Nigeria. *Afr. J. Plant Sci.*, 2: 124-128. 2008.
28. Ekpo A, Eseyin O, Kalu N, Jackson O, Edoho EJ. Studies on the biochemical effects of *Talinum triangulare* in rat. *J. Pharmacol. Toxicol.* 2: 300-303. 2007.
29. [Patrick-Iwuanyanwu KC](#), [Wegwu MO](#), [Ayalogu EO](#). The Protective Nature of Garlic, Ginger and Vitamin E on CCl<sub>4</sub>-Induced Hepatotoxicity in Rats. *Asian J. Biochem.* 2(6):409-414. 2007.
30. Kubena KS, McMurray DN. Nutrition and the immune system: a review of the nutrient-nutrient interactions. *J Am Diet Assoc.*, 96:1156-64.1996.
31. Sirolli V, Ballone E, Garofalo D, Merciaro G, Settefrati N, Di Mascio R, Di Gregorio P, Bonomini M. Platelet Activation Markers in Patients with Nephrotic Syndrome. *Nephron* 91:424-430. 2002.
32. Celik I, Suzek H. The haematological effects of methyl parathion in rats. *J. Hazard. Mater.* 153: 1117-1121. 2008.
33. Hewawasam RP, Jayatilaka KAPW, Pathirana C, Mudduwa LKB. Hepatoprotective effect of *Epaltes divaricata* extract on carbon tetrachloride induced hepatotoxicity in mice. *Indian J. Med. Res.* 120 (1):30-34. 2004.
34. Oboh G. Hepatoprotective property of ethanolic and aqueous extract of fluted pumpkin (*Telfairia occidentalis*) leaves against garlic induced oxidative stress. *J. Med. Food.* 8(4): 560-563. 2005.